

**A NEW SPECIES OF *HEPATOZOON* (APICOMPLEXA: ADELEORINA)
FROM *PYTHON REGIUS* (SERPENTES: PYTHONIDAE) AND ITS
EXPERIMENTAL TRANSMISSION BY A MOSQUITO VECTOR**

Author(s): Michal Sloboda, Martin Kamler, Jana Bulantová, Jan Votýpka, and David Modrý

Source: *Journal of Parasitology*, 93(5):1189-1198.

Published By: American Society of Parasitologists

DOI: <http://dx.doi.org/10.1645/GE-1200R.1>

URL: <http://www.bioone.org/doi/full/10.1645/GE-1200R.1>

BioOne (www.bioone.org) is a nonprofit, online aggregation of core research in the biological, ecological, and environmental sciences. BioOne provides a sustainable online platform for over 170 journals and books published by nonprofit societies, associations, museums, institutions, and presses.

Your use of this PDF, the BioOne Web site, and all posted and associated content indicates your acceptance of BioOne's Terms of Use, available at www.bioone.org/page/terms_of_use.

Usage of BioOne content is strictly limited to personal, educational, and non-commercial use. Commercial inquiries or rights and permissions requests should be directed to the individual publisher as copyright holder.

A NEW SPECIES OF *HEPATOZOON* (APICOMPLEXA: ADELEORINA) FROM *PYTHON REGIUS* (SERPENTES: PYTHONIDAE) AND ITS EXPERIMENTAL TRANSMISSION BY A MOSQUITO VECTOR

Michal Sloboda, Martin Kamler, Jana Bulantová*, Jan Votýpka*†, and David Modrý†

Department of Parasitology, University of Veterinary and Pharmaceutical Sciences, Palackého 1-3, 612 42 Brno, Czech Republic.
e-mail: slobodam@vfu.cz

ABSTRACT: *Hepatozoon ayorgbor* n. sp. is described from specimens of *Python regius* imported from Ghana. Gametocytes were found in the peripheral blood of 43 of 55 snakes examined. Localization of gametocytes was mainly inside the erythrocytes; free gametocytes were found in 15 (34.9%) positive specimens. Infections of laboratory-reared *Culex quinquefasciatus* feeding on infected snakes, as well as experimental infection of juvenile *Python regius* by ingestion of infected mosquitoes, were performed to complete the life cycle. Similarly, transmission to different snake species (*Boa constrictor* and *Lamprophis fuliginosus*) and lizards (*Lepidodactylus lugubris*) was performed to assess the host specificity. Isolates were compared with *Hepatozoon* species from sub-Saharan reptiles and described as a new species based on the morphology, phylogenetic analysis, and a complete life cycle.

Hemogregarines are the most common intracellular hemoparasites found in reptiles. The Hemogregarinidae, Karyolysidae, and Hepatozoidae are distinguished based on the different developmental patterns in definitive (invertebrate) hosts operating as vectors; all 3 families have heteroxenous life cycles (Telford, 1984). The Hepatozoidae is characterized by the formation of large polysporocystic oocysts occurring in the hemocoel of a definitive host (usually a mosquito). In the first intermediate host (lizard, frog), cystic development occurs mainly in the liver; in the second intermediate host (snake), there are typically 2, or more, rounds of merogony in various internal organs (Smith, 1996). Because infections of snakes with *Hepatozoon* sp. have been described in more than 200 species (Levine, 1988), they are considered to be the most frequent hemogregarines in these hosts (Smith, 1996). The majority of descriptions made in the past were based mainly on gametocyte morphology without considering the life cycle, with most of the species being originally referred to as members of the genus *Haemogregarina*. Ball et al. (1967) first revealed that *Haemogregarina rarefasciens* infecting a snake (*Drymarchon corais*) followed the typical life cycle of a species of *Hepatozoon*. Then, later authors transferred several *Haemogregarina* species to *Hepatozoon* (i.e., Smith, 1996; Telford et al., 2002; Paperna and Lainson, 2004). Because a comparison of both gametocyte morphology and sporogonic characters is essential for the definition of a *Hepatozoon* species, the status of all species described without the life cycle is disputable, making the taxonomy of the genus more or less tentative.

Among more than 120 species described from snakes (Smith, 1996), life cycles and host specificity have been studied only in a few cases. Various mosquitoes serve as definitive host, including species of *Culex*, *Aedes*, and *Anopheles*, which are considered to be principal vectors of *Hepatozoon* species from snakes (Smith, 1996). A relatively low host specificity is indicated at the level of snake intermediate hosts, e.g., *Hepatozoon sauritus* has been reported from 4 snake species belonging to

3 genera (Telford et al., 2004). Low host specificity of *Hepatozoon* spp. is supported by experimental transmissions between snakes from different families. Ball (1967) observed experimental parasitemia with *Hepatozoon rarefasciens* in the *Boa constrictor* (Boidae); the vector was *Culex tarsalis*, which had fed on *D. corais* (Colubridae). The host specificity is probably even less at the level of the first intermediate hosts. Various species of lizards, e.g., *Oplurus*, *Podarcis*, and *Tropidurus*, were found to be susceptible to the infection with *Hepatozoon domerguei* or *Hepatozoon terzii*, with the formation of dizoic, tetrazoic, or hexazoic cysts localized in livers of these hosts (Landau et al., 1970; Paperna and Lainson, 2004). Wozniak and Telford (1991) were successful in transmitting *Hepatozoon* sp. from colubrid snakes, *Coluber constrictor* and *Nerodia fasciata*, to the lizards, *Anolis carolinensis* and *Anolis sagrei*. Similarly, various species of amphibians can serve as first intermediate hosts (Smith et al., 1994, 1996). Congenital transmission represents another route of infection, as described by Lowichik and Yaeger (1987) in the ovoviviparous snake *Nerodia fasciata*.

In total, 12 species of *Hepatozoon* have been described to date in snakes from sub-Saharan Africa (Table I); *Hepatozoon robertsonae* (Sambon and Seligmann, 1907) is the only species named from African species of *Python*. In addition to this taxon, there are isolates of hemogregarines reported, but not named, from African *Python regius* and *P. sebae* (Bouet, 1909; Johnson and Benson, 1996). *Python regius* inhabits grasslands, and dry and moist savannas from western to central Africa (Ghana, Benin, Togo, Burkina Faso, Uganda), where high population densities are described even in anthropogenically disturbed habitats (Aubret et al., 2005). *Python regius* is very popular among herpetoculturists, leading to the alarming fact that thousands of these snakes are captured and exported from Africa every year. The greatest number of legally exported snakes originates in Benin (>820,000 exported between 1994 and 2004), Togo (>730,000), and Ghana (>480,000) (www.cites.org). Snakes are usually kept under insufficient conditions before the transport (illegal in many cases), suffering from many pathogens, including parasites (Divers and Malley, 1995).

Herein, we report on the occurrence of *Hepatozoon* sp. in imported *P. regius*, and we describe it as a new species based on results of experimental life cycle study.

Received 18 January 2007; revised 19 February 2007; accepted 4 April 2007.

* Department of Parasitology, Faculty of Science, Charles University, Prague, Czech Republic.

† Centre for Biological Sciences, Institute of Parasitology, Academy of Sciences of the Czech Republic and Faculty of Biological Sciences, University of South Bohemia, České Budějovice, Czech Republic.

TABLE I. A checklist of *Hepatozoon* species described in Afrotropical snakes.

	Definitive host	Intermediate host	Gametocyte size, shape	Locality	Oocyst size, no. of sporocysts	Sporocyst size, no. of sporozoites	Original description
<i>Hepatozoon zambiensis</i>	Not mentioned	<i>Dispholidus typus</i>	14.94–17.79 × 2.35–5.7 μm, bean-shaped	Lochinwar National Park, Zambia	Not mentioned	Not mentioned	Peirce (1984)
<i>Hepatozoon bitis</i>	Not mentioned	<i>Bitis arietans</i>	12.5–14 × 3–4 μm	Great Letaba; Republic of South Africa	Not mentioned	Not mentioned	Fantham and Cantab (1925)
<i>Hepatozoon boodoni</i>	Not mentioned	<i>Boaedon fuliginosus</i>	14–15 × 2–3 μm; 14–15 × 7 μm	Sudan	Not mentioned	Not mentioned	Phisalix (1914)
<i>Hepatozoon brendae</i>	Not mentioned	<i>Psammophis sibilans</i>	16–17 × 3–4 μm	Not mentioned	Not mentioned	Not mentioned	Sambon and Seligmann (1909)
<i>Hepatozoon crotaphopeltis</i>	Not mentioned	<i>Crotaphopeltis hotamboeia</i>	20 × 2 μm, slender vermicules	Entebbe; Uganda	Not mentioned	Not mentioned	Hoare (1932)
<i>Hepatozoon dogieli</i>	Not mentioned	<i>Bitis gabonica</i>	14 × 6 μm, bean-shaped	Mabira, Uganda	Not mentioned	Not mentioned	Hoare (1920)
<i>Hepatozoon enswerae</i>	Not mentioned	<i>Naja melanoleuca</i>	19 × 3 μm, slender vermicules; 15 × 3.8 μm, bean-shaped	Entebbe, Kampala; Uganda	Not mentioned	Not mentioned	Hoare (1932)
<i>Hepatozoon minchini</i>	Not mentioned	<i>Crotaphopeltis degeni</i>	13–14 × 3–4 μm, sausage-shaped	Kavirondo Gulf of Lake Viktoria; Kenya	Not mentioned	Not mentioned	Garnham (1950)
<i>Hepatozoon musotae</i>	Not mentioned	<i>Boaedon lineatus</i>	17 × 3.8–4.7 μm, bean-shaped; 15.2 × 6.6 μm, broad forms	Entebbe; Uganda	Not mentioned	Not mentioned	Hoare (1932)
<i>Hepatozoon robertsonae</i>	Not mentioned	<i>Python regius</i> and <i>Python sebae</i>	12–16 × ? μm	Gambia	Not mentioned	Not mentioned	Sambon and Seligmann (1907)
<i>Hepatozoon vubirizi</i>	Not mentioned	<i>Simocephalus butleri</i>	15–17 × 3.8–4.7 μm, bean-shaped	Entebbe; Uganda	Not mentioned	Not mentioned	Hoare (1932)

MATERIALS AND METHODS

Examination of imported snakes and ticks

In total, 55 *P. regius* were examined. A group was imported by a pet-trader under license from Ghana in 2005. All snakes were measured, weighed, and sexed using cloacal probing (DeNardo, 1996), and they were examined for ectoparasites. Blood samples were obtained by ventral tail venipuncture (Jenkins, 1996). Blood smears were rapidly air-dried and fixed in absolute methyl alcohol, and staining was done using the May-Grünwald-Giemsa method. The remaining blood was stored in absolute ethanol. Blood smears were examined using an Olympus AX70 microscope. Ten thousand erythrocytes from each blood smear were examined for hemogregarines, and parasitemia was estimated for each specimen (percentage). Measurements given (gametocytes, erythrocytes) originated from a single positive snake obtained to perform experimental infections, whereas extraerythrocytic stages (free gametocytes) were measured in another snake from the same group. Measurements are given in micrometers as means, followed by the range in parentheses, and the number of parasites measured (n). Statistical analysis was performed using chi-square, nonparametric Mann-Whitney *U*-test (prevalence and parasite load, respectively) and nonparametric Steel test (gametocyte morphology comparison).

Ticks naturally occurring on imported pythons were collected manually from each snake, counted, and kept alive in plastic vials before their dissection. Identification of the ticks was accomplished following Hoogstral (1956). In total, 100 ticks collected from all the pythons (n

= 55) were randomly chosen and dissected, and at least 1 tick was dissected from each snake. Dissections were performed by placing the ticks on a slide with basic saline solution (0.75%) and by an incision around the idiosoma on the marginal groove. The dorsal tegument was folded back and the body cavity was flushed with cold physiological solution (6 C) to increase the rigidity of the internal organs and to facilitate the search for oocysts. The suspension obtained, as well as the gut and salivary glands, were examined using an Olympus AX70 microscope.

Experimental infections

Mosquitoes: Laboratory-reared *Culex quinquefasciatus* were used to perform experimental infections. Mosquitoes were maintained in the Plexiglas[®] box system (Olejníček, 1993). One positive *P. regius* from the imported group was heated in a thermostat (37 C) for 3 hr and moved to a Plexiglas box with *Cx. quinquefasciatus* overnight. Then, the snake was removed as well as nonfed mosquito females. The remaining mosquitoes were kept in the same box at 25 C and 70% humidity in a 12/12-hr day/night cycle, and they were provided with water and a 10% (w/v) sucrose solution. Mosquitoes were dissected at 33–35 days postinfection (DPI). After being anesthetized (1 min in a freezer), they were placed on a slide with basic saline solution (0.75%) and dissected. Samples of the proboscis, salivary gland, gut, fat body, and hemocoel were examined using an Olympus AX70 microscope.

Snakes: One specimen of *P. regius* and 1 *Lamprophis fuliginosus*,

both juveniles, were used for experimental infections. Snakes were previously checked weekly, with negative results, for the presence of hemogregarines for 12 consecutive weeks before inoculation. Oocysts used for inoculation originated from an experimentally infected *Cx. quinquefasciatus*. Thirty-four DPI, oocysts were disrupted, together with saline solution by using a vortex machine, and sporocysts were counted in Bürker's chamber. Then, both snakes were inoculated perorally with 1,500 sporocysts by an esophageal tube. Blood was taken, and a presence of gametocytes in peripheral blood was checked weekly in blood smears stained as described above.

Two juvenile boas (*B. constrictor*) were infected by force feeding 2 specimens of *Cx. quinquefasciatus* previously fed on positive *P. regius* originating from the group of imported animals; both snakes were fed mosquitoes 30 DPI. The exact number of sporocysts used for *B. constrictor* inoculation was not estimated. Snakes were kept separately in glass cages at \bar{x} of 25 C and 70% humidity in a 12/12-hr day/night cycle, and they were fed laboratory mice weekly. Blood samples were examined weekly as described above.

Snakes from both experiments were killed by an overdose of ether 60, 180 (*B. constrictor*), and 90 (*P. regius*, *L. fuliginosus*) DPI, and then they were dissected. Samples of heart, lungs, liver, stomach, intestine, and kidney were obtained during necropsy and preserved in 10% buffered formalin. Histological sections were stained with hematoxylin and eosin.

Lizards: In total, 6 *L. lugubris*, all juveniles, were used for experimental infections. Animals were captive bred. Considering the small size, blood samples were obtained by tail clipping. Lizards were maintained in the same conditions as snakes and fed commercially bred crickets twice a week. Two different experimental doses and schemes were used. Four lizards were infected with 300 sporocysts obtained as described above for *P. regius* and *L. fuliginosus*. From the latter 4 lizards, 2 were infected perorally and 2 intraperitoneally. Blood samples were obtained 30 and 90 DPI, at which time the lizards were also killed and necropsied. In the second trial, 2 lizards were force fed each with 2 mosquitoes previously fed on infected *P. regius*. Each lizard was killed 60 DPI and necropsied. Blood samples were obtained 8 DPI and during dissection. Samples for histological sections from the lizards in both experimental trials were obtained and handled the same way as those from experimentally infected snakes. One intraperitoneally infected lizard died 83 DPI, and it was found in the late stage of autolysis; thus, no samples for histological sections were obtained from this specimen.

DNA extraction, polymerase chain reaction, and sequencing

Intact oocysts and released sporocysts were removed from dissected mosquitoes and kept in basic saline solution (0.75%) at -20 C. Isolation of total DNA and sequencing have been described previously (Votýpka et al., 2002). The 18S rDNA gene was amplified using eukaryote-specific primers MedlinA (CGT GTT GAT CCT GCC AG) and MedlinB (TGA TCC TTC TGC AGG TTC ACC TAC) (Medlin et al., 1988). Three independent amplicons were gel-isolated (QIAGEN, Valencia, California), and they were directly sequenced on an automated DNA sequencer (ABI Prism 310 Genetic Analyzer; Applied Biosystems, Foster City, California) using the BigDye 3.1 kit (Applied Biosystems).

Phylogenetic analysis

The small subunit ribosomal RNA (18S rDNA) was used to establish the phylogenetic position of *Hepatozoon ayorgbor* n. sp. Obtained DNA sequence data were compared with those in the GenBank database using BLAST® algorithm. All sequences of the small subunit rRNA genes of *Hepatozoon* spp. available in public databases, except incomplete sequences, were used in our analyses. Appropriate sequences of 18S rDNA were aligned using the program Clustal X 1.18 (Thompson et al., 1997). Alignment was manually checked and corrected using the program BIOEDIT (Hall, 1999); gaps, as well as ambiguously aligned regions, were omitted from further analysis. For analyses presented here, 35 operational taxonomic units (OTUs) and 1,786 characters were composed. Phylogenetic analysis was performed using maximum parsimony, maximum likelihood, and Bayesian, with the program package PAUP4.0b10 (Swofford, 2001), PhyML (Guindon and Gascuel, 2003), and MrBayes 3.0 (Huelsenbeck and Ronquist, 2001). MP trees (addseq = random, nrep = 10, tree bisection-reconnection branch swapping al-

gorithm) were constructed using PAUP, and bootstrap analyses were performed with 1,000 replicates. ML trees were constructed using GTR model for nucleotide substitutions with γ -distribution in 8+1 categories. Bootstrap analysis was computed in 200 replicates using the same model with γ -distribution in 4 categories and all parameters estimated from the data set. A Bayesian tree was constructed in the program MrBayes 3.0 (ngen = 2,000,000, nst = 6, basefreq = estimate, rates = invgamma, burnin = 1,000). The nucleotide sequence of the 18S rDNA of the new species has been deposited at the GenBank under the accession no. EF157822.

RESULTS

Examination of imported snakes

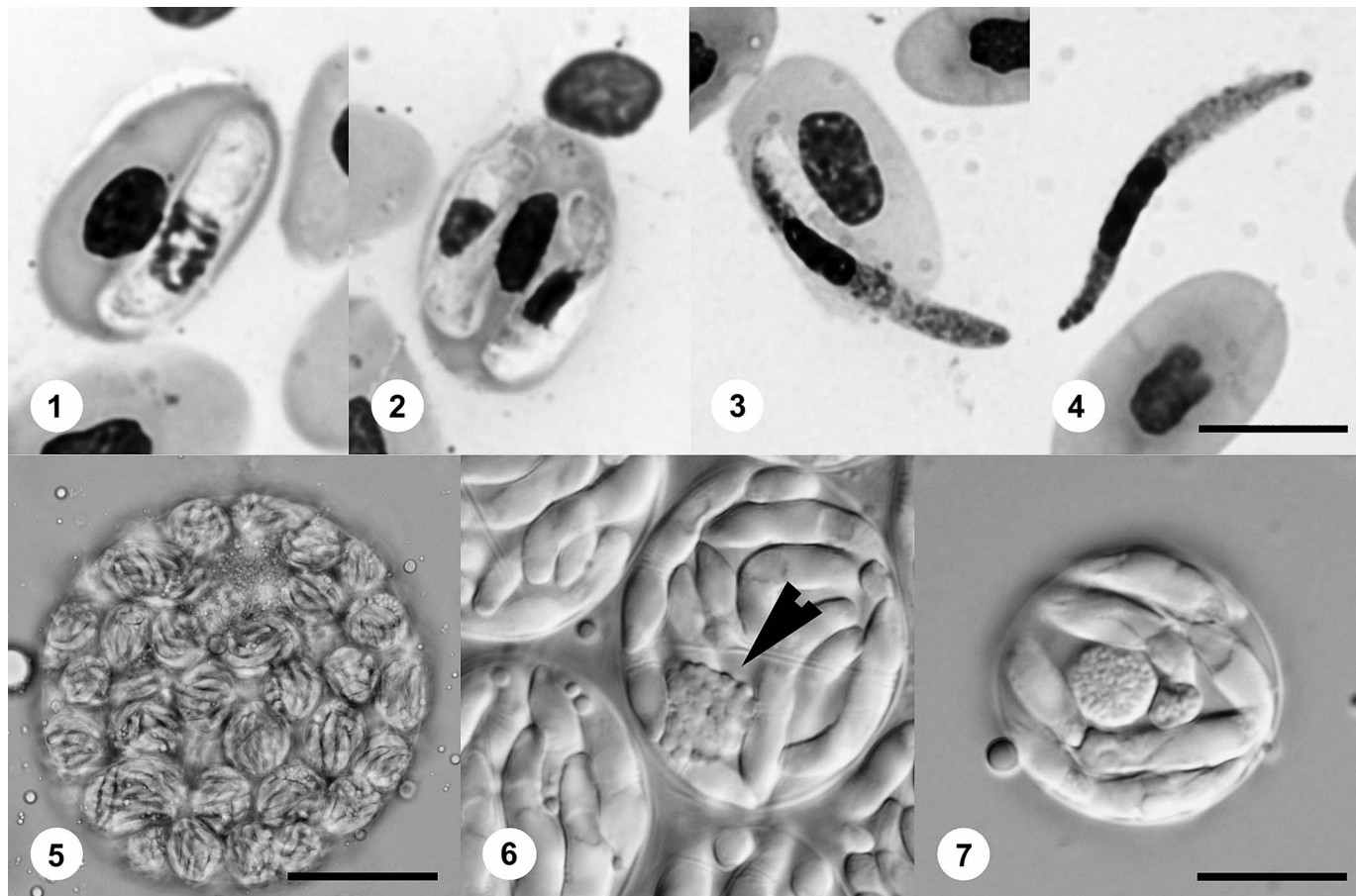
Except for 2 subadult specimens, all the snakes were adults with total length exceeding 90 cm. From 55 specimens in total, 30 (55.5%) were males and 25 (45.5%) females. On average, males weighed 955.8 g (650–1,350) and females weighed 1,119.2 g (760–1,450). Intraerythrocytic stages (gametocytes) of *Hepatozoon* sp. were found in 43 (78.2%) specimens (Fig. 1). The number of infected snakes was 22 of 30 (73.3%) in males and 21 of 25 (84%) in females, with no significant difference between sexes. Localization of gametocytes was mainly inside the erythrocytes; double infections of erythrocytes were observed rarely (Fig. 2). Gametocytes emerging from infected erythrocytes were seen (Fig. 3), and extracellular forms were found in 15 (27.3%) specimens, 3 males and 12 females (Fig. 4). Average parasitemia in infected animals was 0.64% (0.02–4.12) in males and 0.85% (0.01–3.07) in females; no significant difference was observed between infected animals of both sexes.

Tick infestation with *Aponomma latum* was found in 50 (90.9%) specimens of *P. regius* examined with \bar{x} of 7.57 (1–35) ticks in male and 6.24 (2–20) in female of infested snakes. Neither oocysts nor other developmental stages of hemogregarines were found during dissections of all 100 ticks. A single male of *Amblyomma nuttalli* was found on 1 snake; no oocysts were present during dissection.

Experimental infections

Mosquitoes: In total, 60 mosquitoes fed on a positive snake, and 43 mosquitoes (71.6%) were positive during the dissections and examination at 34 DPI. Sporulated oocysts were found exclusively in the hemocoel of thorax and abdomen (Fig. 5); none was observed in proboscis and salivary gland. The average number of oocysts per infected mosquito was 4.4 (1–17), and 21 oocysts were found disrupted during the dissections. Intact oocysts measured 251.5×247.7 (58–638 \times 58–638; n = 165), each containing 228.53 (33–1013, n = 17) sporocysts. Sporocysts measured 35.4×23.6 (20–53 \times 18–42; n = 30) and contained 21.3 (14–38) sporozoites; a residual body was present (Figs. 6, 7). Sporozoites were banana-shaped, 18.8×4.3 (17–21 \times 3–5; n = 30), not possessing a residual body.

Snakes: In all experimentally infected snakes, gametocytes (Figs. 8, 9, 10, 11) were observed in peripheral blood in various intervals after the inoculation (for measurements, see Table II). Significant difference in both length and width of gametocytes was observed in experimentally infected *P. regius* and *B. constrictor* no. 2 compared with those of naturally infected *P. regius*. Remaining experimental snakes differed in either length (*B. constrictor* no. 1) or width (*L. fuliginosus*) compared with



FIGURES 1–7. *Hepatozoon ayorgbor* n. sp. (1). Single gametocyte in the erythrocyte of naturally infected *Python regius*. (2) Double infection of the erythrocyte. (3) Gametocyte emerging from the host cell. (4) Free (exoerythrocytic) gametocyte. (5) Oocyst of *H. ayorgbor* n. sp. in the hemocoel of abdomen in experimentally infected *Culex quinquefasciatus* 34 DPI. (6) Detailed view of the sporocysts in intact oocyst. Note prominent sporocyst residuum (arrowhead). (7) Sporocyst after disruption of oocyst. Bars = 10 μ m, except 5 = 50 μ m.

naturally infected snakes ($P < 0.001$). In histological sections, meronts in various stages of development were found both in *P. regius* and *L. fuliginosus*. In *P. regius*, a single meront measuring 18×11 was found in liver tissue and contained 26 merozoites (Fig. 12). In *L. fuliginosus*, 2 undivided (uninuclear) meronts measuring 12×7 and 15×10 were found in liver tissue, and the multinuclear meronts localized in liver measured 18×11.3 ($10\text{--}24 \times 6\text{--}18$; $n = 10$) (Figs. 13, 14). Undivided meronts found in endothelial cells of capillaries in the lungs measured 12.1×9.7 ($8\text{--}16 \times 7\text{--}17$; $n = 10$), multinuclear 16.4×9.7 ($11\text{--}20 \times 6\text{--}12$; $n = 10$). The meront nuclei were usually peripherally disposed, and each divided meront contained 5–24 merozoites (Figs. 15–17).

Lizards: No gametocytes in the bloodstream were found in all animals in various periods after infection in both experimental groups. Similarly, no endogenous stages were present in histological sections of any organ examined.

DESCRIPTION

Hepatozoon ayorgbor n. sp.

(Figs. 1–7, 14)

Description of gametocytes: Gametocytes are broadly elongate 12.2×2.9 ($11\text{--}13 \times 2\text{--}3.5$), with elongated nuclei 5.2×1.6 ($4\text{--}6.5 \times 1.5\text{--}2$), $n = 30$, not recurved (Figs. 1, 2). Nuclei of infected erythrocytes 7

$\times 2.5$ ($6\text{--}9.5 \times 1.5\text{--}3$), usually forced to one side of host cell. Nuclei of uninfected erythrocytes measuring 6.5×3.5 ($5\text{--}7 \times 3\text{--}4.5$). Mean size of uninfected erythrocytes 19.1×9.75 ($14\text{--}22 \times 8.5\text{--}12$), $n = 30$ and 19.0×9.3 ($17\text{--}21 \times 8\text{--}10$), $n = 30$ in infected erythrocytes. Extracellular (free) gametocytes 23.26×2.1 ($20\text{--}25 \times 1.5\text{--}2.5$), $n = 30$ with nucleus always in second half of gametocyte (Fig. 4).

Description of sporulated oocysts: Stages of sporogony in experimentally infected *Cx. quinquefasciatus* observed within hemocoel of thorax and abdomen. Oocysts (Fig. 5) ovoidal, 251.51×247.72 ($58\text{--}638 \times 58\text{--}638$; $n = 165$), SI (length/width) = 1.01. Each oocyst with 228.53 ($33\text{--}1013$; $n = 17$) sporocysts.

Description of sporocysts and sporozoites: Sporocysts (Figs. 6, 7) spherical to ovoidal 35.47×23.67 ($20\text{--}53 \times 18\text{--}42$; $n = 30$), SI = 1.50 each with 21.3 ($14\text{--}38$; $n = 30$) sporozoites.

Description of meronts: Single meront as found in experimentally infected type host, localized in liver tissue, measured 18×11 and contained 26 merozoites (Fig. 14).

Taxonomic summary

Type host: *Python regius* Shaw, 1802.

Other hosts (experimental, this study): *Lamprophis fuliginosus* Boié, 1827; *Boa constrictor* Linnaeus, 1758.

Type locality: Ghana.

Prevalence: Forty-three of 55 *P. regius* examined.

Site of infection: Erythrocytes, liver, and lung.

Material deposited: Hapantotype blood films and photosyntypes of sporulated oocysts deposited in Type collection of Department of Parasitology, University of Veterinary and Pharmaceutical Sciences Brno, Czech Republic.

TABLE II. Morphometry of gamonts and erythrocytes in naturally and experimentally infected snakes.

Snake species	First gamonts in peripheral blood (DPI)	Gamonts (n = 30)	Infected erythrocytes (n = 30)	Noninfected erythrocytes (n = 30)
<i>Python regius</i> (70 DPI)	69	13.1 × 3.47 (9–14 × 2–4.5)	19.17 × 9.48 (17–21 × 7–11)	18.03 × 8.28 (15.5–20 × 7–10)
<i>Lamprophis fuliginosus</i> (70 DPI)	44	12.05 × 3.47 (8–14 × 3–4.5)	16.98 × 9.2 (15.5–21 × 8–11)	16 × 7.9 (14.5–18 × 7–9.5)
<i>Boa constrictor</i> no. 1 (60 DPI)	37	10.73 × 3.33 (8–12 × 2–4)	16.90 × 10.53 (14–20 × 9–14)	17.97 × 8.13 (13–20 × 6–10)
<i>Boa constrictor</i> no. 2 (60 DPI)	44	11.13 × 3.07 (8–13 × 1–4)	18.33 × 9.53 (13–22 × 7–12)	18.97 × 8.87 (15–21 × 7–13)

Etymology: The specific epithet reflects the vernacular name used for *P. regius* by local people in Ghana (Gorzula et al., 1997). The name is given, according to the ICZN, as a noun in apposition.

Phylogenetic analysis

We have sequenced the 18S gene representing the putative new *Hepatozoon* species. The final data set contains all sequenced species of *Hepatozoon*, as well as representatives of all major branches of Apicomplexa parasites. The tree was rooted using the colpodellids as an outgroup.

Hepatozoon ayorgbor n. sp. clusters within the other species from this genus, and all methods used strongly support its affiliation with this clade. Major branches are well supported, and the branching order is not influenced by the use of different outgroups. The obtained tree revealed the monophyly of *H. ayorgbor* n. sp. with *Hepatozoon* sp. (Boiga), the only other available *Hepatozoon* species from snakes, a relationship supported by 97–99% bootstrap by all methods used (Fig. 18).

In summary, *H. ayorgbor* clusters in all performed analyses together with all other species from *Hepatozoon*, with 100% bootstrap support and this genus seems to represent a separate cluster within hemogregarines.

DISCUSSION

Life cycle and morphology

Hepatozoon spp. includes the most frequent hemoparasites infecting ophidian hosts (Levine, 1988). In contrast to the *Hepatozoon* spp. infecting mammals, *H. kisrae* cycling between *Agama stellio* and *Hyalomma* cf. *aegyptium* is the only known species from reptiles transmitted by ticks (Paperna et al., 2002); Ball et al. (1969) was successful in transmission of *Hepatozoon fusifex* from *B. constrictor* to *Amblyomma dissimile* under experimental conditions. Infestation with *Aponomma* spp. ticks is commonly reported in imported *P. regius* (Hammond and Dorset, 1988; Divers and Malley, 1995; Kenny et al., 2004); however, none of *Aponomma latum* and/or *Amblyomma nuttalli* feeding on infected animals and examined in our study contained developmental stages of hemogregarines. Similarly, Wozniak and Telford (1991) were not able to transmit undetermined *Hepatozoon* species to *Ornithodoros moubata* fed on infected colubrid snakes.

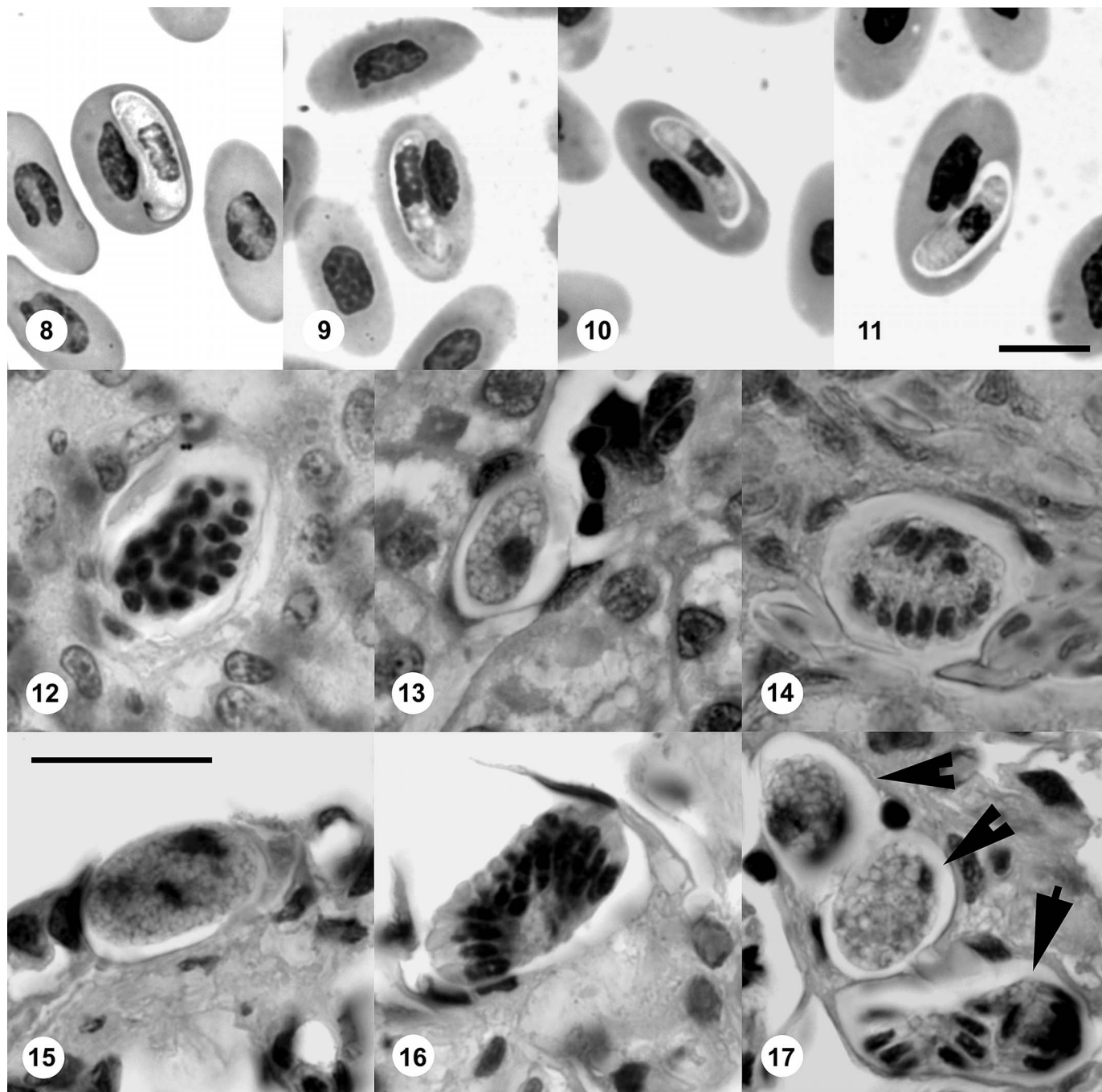
Mosquitoes evidently represent principal vectors of *Hepatozoon* spp. in ophidian hosts. The host specificity on the level of definitive host is rather low, and various species of *Culex*, *Aedes*, and *Anopheles* are proved to be susceptible to the experimental infection, i.e., *Culex tarsalis*, *Cx. pipiens molestus*, *Cx. pipiens fatigans*, *Cx. quinquefasciatus*, *Cx. territans*, *Aedes aegypti*, *Ae. sierrensis*, and *Anopheles albimanus* (Ball et al.,

1967; Booden et al., 1970; Landau et al., 1972; Bashtar et al., 1984, 1991; Nadler and Miller, 1984; Paperna and Lainson, 2004).

The gamogony in definitive hosts ends by the formation of multisporecystic oocysts in the hemocoel of the abdomen and thorax within fat body cells (Smith, 1996). High variability in oocyst and sporocyst size was described by several authors (e.g., Smith, 1996) and was confirmed in present study. Size of the *H. ayorgbor* n. sp. oocysts ranged 58–638 × 58–638 μm, and high variability in the number of sporocysts (33–1,013) depended on the oocyst size.

The host specificity of hemogregarines at the level of the snake host is only vaguely understood. In older studies, the occurrence of gametocytes in a new host was often used to justify the description of a new species. In contrast, limited experimental studies showed remarkably low host specificity. *Hepatozoon rarefaciens* was successfully transmitted from *D. corais* to *Pituophis catenifer* (Chao and Ball, 1969), and also to *B. constrictor* (Ball et al., 1967). Documented transmissions between distantly related snakes suggest the host spectrum to be delimited by the host ecology rather than host phylogenetic relationships. In our study, we successfully transmitted *H. ayorgbor* n. sp. from *P. regius* to both Afrotropical (*L. fuliginosus*) and Neotropical (*B. constrictor*) snakes that further confirms the assertion regarding low host specificity. In contrast, under natural conditions, *Hepatozoon* spp. indicate narrower host specificity than in the laboratory. Telford et al. (2001) studied *Hepatozoon* species in a community of 5 snake species in Florida. In that investigation, each snake species was parasitized by at least 1 characteristic *Hepatozoon* species and no cross-infections were identified. A similar observation was made for *Hepatozoon guttata* and *Hepatozoon sistruri* (Telford et al., 2002). In *H. sauritus*, however, a potential to infect more than 1 host snake species was observed under natural conditions, and the conspecificity of isolates in different snake species was confirmed by gametocyte morphology and by genome analysis (Telford et al., 2004). Interestingly, a short-term parasitemia was also observed in lizards experimentally fed with mosquitoes that had fed on snakes infected either with undescribed *Hepatozoon* sp. (Booden et al., 1970; Oda et al., 1971) or *H. domerguei* (Landau et al., 1972).

In ophidian hosts, merogonic development occurs in 1, or more, internal organs. Two types of meronts, namely, macromeronts (Y meronts) and micromeronts (X meronts), are distinguished in some studies (Smith et al., 1994, 1996; Telford et



FIGURES 8–11. Gametocytes of *Hepatozoon ayorgbor* n. sp. in experimentally infected snakes, all in the same scale. (8) Gametocytes in erythrocytes of *Python regius*. Bar = 10 μ m. (9) Gametocytes in erythrocytes of *Lamprophis fuliginosus*. (10–11) Gametocytes in erythrocytes of *Boa constrictor*.

FIGURES 12–17. Merogony in experimentally infected snakes, all in the same scale. (12) Divided meront in liver tissue of *Python regius*. Undivided (13) and divided (14) meront in liver tissue of *Lamprophis fuliginosus*. (15) Undivided meront in lung tissue of *L. fuliginosus*. Bar = 20 μ m. (16) Divided meront in lung tissue of *L. fuliginosus*. (17) Divided (arrow) and 2 undivided (arrowheads) meronts in lung tissue of *L. fuliginosus*.

al., 2001, 2002). Macromeronts are the earlier stage of merogony, and they contain large macromerozoites. These do not invade erythrocytes, but other tissue cells where they give rise to further generations of merogony. Micromeronts form later in development and produce smaller micromerozoites, which circulate for a short time in the bloodstream before they enter

erythrocytes. The merogonic development is completed within 4–7 wk after the infection (Smith, 1996). The relatively long interval (60 days) between the infection and dissection of our experimentally infected snakes and the simultaneous presence of intraerythrocytic gametocytes and tissue meronts suggest observed meronts to be micromeronts.

An intriguing phenomenon in the life cycle of *Hepatozoon* spp. in snakes is the presence of free extracellular gametocytes, previously described by several authors (Telford et al., 2001, 2002, 2004). Although free zoitelike stages observed in our study resemble micromerozoites in their general appearance, they are gametocytes that evidently emerged from erythrocytes (Figs. 3, 4). However, the role of these stages in the life cycle, if any, remains unknown.

Generally, there are 2 described ways the snake host becomes infected by *Hepatozoon* spp.: (1) the ingestion of vector and (2) predation upon first intermediate host. Oral ingestion of an infected mosquito by snakes is a proved experimental method of transmission (Telford et al., 2001, 2004). In our study, we transmitted the infection to snakes the same way. However, considering the feeding biology of snakes, such a route of infection is extremely improbable under natural conditions.

Existence of a first intermediate host is considered to be the most important aspect in the transmission of *Hepatozoon* species to snakes. In these cases, cysts containing up to 6 cystozoites were localized in the liver tissue of infected saurian hosts (Landau, 1970; Paperna and Lainson, 2004). In *Hepatozoon sipedon* and *Hepatozoon sirtalis*, an amphibian first intermediate host was confirmed (Smith et al., 1994, 1999; Telford et al., 2001).

In our study, we inoculated a total of 6 *L. lugubris* to determine whether this lizard species can serve as a first intermediate host of the new *Hepatozoon* species. None of the experimentally inoculated lizards possessed either gametocytes in the peripheral bloodstream or cysts or other endogenous stages in their internal organs. The ability of *H. ayorgbor* n. sp. to infect other lizard species should be further examined. The diet of *P. regius* consists naturally of small mammals, mainly ground-dwelling rodents, e.g., species of *Tatera* and *Taterillus*, and birds (Luiselli et al., 2001; Spawls et al., 2004) depending on age, size, and sex of the snake (Luiselli et al., 2001). It is probable that the specificity of *Hepatozoon* spp. at the level of the first intermediate host reflects the trophic relationships between snakes and their prey. In addition, Telford et al. (2001) found oocysts in proboscides of mosquitoes infected with *Hepatozoon pictiventris*. However, in our study, oocysts were found only in the hemocoel of mosquitoes' abdomens and thoraces. Thus, the role of rodents and birds in the life cycle of *H. ayorgbor*, as well as the possibility of inoculative transmission of *Hepatozoon* spp. by mosquito vectors, should be elucidated.

Pathogenicity

Pathogenicity of *Hepatozoon* infection for invertebrate (definitive) hosts was described previously by several authors. Wozniak and Telford (1991) observed 40% mortality in *Ae. aegypti* in experimental conditions during the first 48 hr post-infection, and many mosquitoes that survived seemed weak and lethargic. Similarly, a high mortality in a group of *Cx. quinquefasciatus* experimentally fed on *B. constrictor* infected with *H. terzii* was described by Paperna and Lainson (2003, 2004); no mosquitoes survived more than 9 days after feeding. Dependence between high level of parasitemia of a snake and consequent mortality in mosquito fed on such a host was described (Ball et al., 1967).

However, pathogenicity in infected snakes (natural interme-

diolate hosts) is considered to be low (Nadler and Miller, 1984, 1985; Wozniak et al., 1994). A slight anemia, hypertrophy of erythrocytes, and plasma membrane alteration associated with *Hepatozoon* sp. infection in snakes was described by Telford (1984). Granulomatous hepatitis associated with *Hepatozoon* sp. meronts was observed in *Nerodia fasciata pictiventris* (Wozniak et al., 1998). Caudell et al. (2002), studying the effect of *Hepatozoon* sp. infection on blood chemistry and health of *Boiga irregularis*, found no significant difference between infected and noninfected snakes. In the present study, all experimental animals were in good condition without any visible changes in their health status. Neither gross pathological nor histological lesions were found in necropsied python.

Phylogeny

The morphological features and molecular phylogenetic analysis definitively identify the organism as a new species of *Hepatozoon*. To our knowledge, the sequence of *H. ayorgbor* n. sp. represents the second sequence of *Hepatozoon* from a snake and the first from Africa continent. Therefore, detailed characterization of this DNA sequence was not possible.

Taxonomy

Twelve species of *Hepatozoon* have been described to date from African snakes in sub-Saharan Africa (Table I). *Hepatozoon robertsonae* (Sambon and Seligmann, 1907) is the only species described from an African member of the Pythonidae. The latter species was described (Sambon and Seligman, 1907) based on data presented by Roberson (1906) as a description of *Trypanosoma pythonis*. However, because the type host of this hemogregarine is not clear (probably *P. regius* or *P. sebae*), and the data rather limited, we consider *H. robertsonae* to be a nomen nudum. Additionally, there are further isolates of hemogregarines reported, but not described, from African *P. regius* and *P. sebae* (Bouet, 1909; Johnson and Benson, 1996). Thus, a first species of *Hepatozoon* from *P. regius* is described herein. Gametocytes of *H. ayorgbor* n. sp. are shorter than those of previously described species in snakes from the sub-Saharan realm. *Hepatozoon dogieli* gametocytes are the most similar in length, but much wider. Unfortunately, all the descriptions lack the information about oocysts/sporocysts morphometry.

All previous descriptions of *Hepatozoon* species from sub-Saharan snakes lack information about the life cycle and stages in definitive hosts, and the host specificity itself has only limited use in the *Hepatozoon* spp. taxonomy. Even in our limited group of experimental snakes, the gametocyte morphology varied (Table II), and it can be only barely used as a key diagnostic feature. Significant difference in both length and width of gametocytes compared with those in naturally infected *P. regius* was observed in experimentally infected snake of the same species. Moreover, the entire taxonomy of *Hepatozoon* spp. in sub-Saharan Africa prevents a comparison of new findings with described taxa. To prevent further taxonomic obstacles, description of new taxa should contain the morphological data, together with life cycle studies, and, whenever possible, molecular data.

ACKNOWLEDGMENTS

We are grateful to Miloslav Jirků for help with preparing the figures and for help with the experimental animals as well as for critical com-

ments on the manuscript; to Pavel Široký for help with the determination of the ticks; and to Mirko Vyskočil for help with statistical analysis. This study was supported by grants from Grant Agency of the Czech Republic (524/03/D104 and 524/03/H133), and, in part, also by Ministry of Education (0021620828-LC 06009).

LITERATURE CITED

- AUBRET, F., X. BONNET, M. HARRIS, AND S. MAUMELAT. 2005. Sex differences in body size and ectoparasite load in the ball python, *Python regius*. *Journal of Herpetology* **39**: 315–320.
- BALL, G. H. 1967. Some blood sporozoans from east African reptiles. *Journal of Protozoology* **14**: 198–210.
- , J. CHAO, AND S. R. TELFORD, JR. 1967. The life history of *Hepatozoon rarefaciens* (Sambon and Selingmann, 1907) from *Drymarchon corais* (Colubridae) and its experimental transfer to *Constrictor constrictor* (Boidae). *Journal of Parasitology* **53**: 897–909.
- , ———, AND ———. 1969. *Hepatozoon fusifex* sp. n., hemogregarine from *Boa constrictor* producing marked morphological changes in infected erythrocytes. *Journal of Parasitology* **55**: 800–813.
- BASHTAR, A. R., F. A. ABDEL-GHAFFAR, AND H. MEHLHORN. 1984. *Hepatozoon aegypti* nov. sp. 3. Electron microscope studies on the gamogony and sporogony inside the vector *Culex pipiens molestus*. *Zeitschrift für Parasitenkunde* **70**: 53–65.
- , ———, AND M. A. SHAZLY. 1991. Life cycle of *Hepatozoon mehlhorni* sp. nov. in the viper *Echis carinatus* and the mosquito *Culex pipiens*. *Parasitology Research* **77**: 402–410.
- BOODEN, T., J. CHAO, AND G. H. BALL. 1970. Transfer of *Hepatozoon* sp. from *Boa constrictor* to a lizard, *Anolis carolinensis*, by mosquito vectors. *Journal of Parasitology* **56**: 832–833.
- BOUET, G. 1909. Hémogregarines de l'Afrique occidentale française. *Comptes Rendus des Séances et Mémoires de la Société de Biologie* **66**: 741–743.
- CAUPELL, J. N., J. WHITTIER, AND M. R. CONOVER. 2002. The effects of haemogregarine-like parasites on brown tree snakes (*Boiga irregularis*) and slaty-grey snakes (*Stegonotus cucullatus*) in Queensland, Australia. *International Biodeterioration & Biodegradation* **49**: 113–119.
- CHAO, J., AND G. H. BALL. 1969. Transfer of *Hepatozoon rarefaciens* (Sambon and Selingmann, 1907) from the indigo snake to a gopher snake by a mosquito vector. *Journal of Parasitology* **55**: 681–682.
- DE NARDO, D. 1996. Reproductive biology. In *Reptile medicine and surgery*, D. R. Mader (ed.). W. B. Saunders Company, Philadelphia, Pennsylvania, p. 264–276.
- DIVERS, S. J., AND D. A. MALLEY. 1995. Disease and mortality of 397 illegally imported royal pythons (*Python regius*). Fifth International Colloquium on the Pathology of Reptiles and Amphibians, 31.3–2.4.1995, Alphen Aan Den Rijn, The Netherlands, p. 215–230.
- FANTHAM, H. B., AND M. A. CANTAB. 1925. Some parasitic protozoa found in South Africa. VIII. *South African Journal of Science* **22**: 346–354.
- GARNHAM, P. C. C. 1950. Blood parasites of East African vertebrates, with a brief description of exo-erythrocytic schizogony in *Plasmodium pitmani*. *Parasitology* **40**: 328–337.
- GORZULA, S., W. O. NSIAH, AND W. ODURO. 1997. Survey of the status and management of the Royal Python (*Python regius*) in Ghana. Report to the Secretariat of the Convention on International Trade in Endangered Species of Wild Fauna and Flora (CITES), Geneva, Switzerland, p. 15.
- GUINDON, S., AND O. GASCUEL. 2003. A simple, fast and accurate algorithm to estimate large phylogenies by maximum likelihood. *Systematic Biology* **52**: 696–704.
- HALL, T. A. 1999. BioEdit: A user-friendly biological sequence alignment editor and analysis program for Windows 95/98/NT. *Nucleic Acids Symposium Series* **41**: 1782–1791.
- HAMMOND, D. L., AND W. A. DORSET. 1988. Tick infestation in a ball python (*Python regius*). *Companion Animal Practice* **2**: 39–40.
- HOARE, C. A. 1920. On some new haemogregarines from British East Africa. *Parasitology* **12**: 315–327.
- . 1932. On protozoal blood parasites collected in Uganda. *Parasitology* **24**: 210–224.
- HOOGSTRAL, H. 1956. African Ixodoidea, Vol. I. Ticks of the Sudan with special reference to equatorial province and with preliminary reviews of the genera *Boophilus*, *Margaropus* and *Hyalomma*. U.S. Department of the Navy Bureau of Medicine and Surgery, Washington, D.C., p. 263–266.
- HUELSENBECK, J. P., AND F. RONQUIST. 2001. MrBayes: Bayesian inference of phylogenetic trees. *Bioinformatics* **17**: 754–755.
- JENKINS, J. R. 1996. Diagnostic and clinical techniques. In *Reptile medicine and surgery*, D. R. Mader (ed.). W. B. Saunders Company, Philadelphia, Pennsylvania, p. 264–276.
- JOHNSON, J. H., AND P. A. BENSON. 1996. Laboratory reference values for a group of captive Ball Pythons (*Python regius*). *American Journal of Veterinary Research* **57**: 1304–1307.
- KENNY, M. J., S. E. SHAW, P. D. HILLYARD, AND A. B. FORBES. 2004. Ectoparasite and haemoparasite risks associated with imported exotic reptiles. *Veterinary Record* **154**: 434–435.
- LANDAU, I., A. G. CHABAUD, AND J. C. MICHEL. 1970. Mise en évidence d'un double mode de transmission chez un *Hepatozoon* de reptiles malgaches. *Comptes Rendus Hebdomadaires des Séances de l'Académie des Sciences, Série D, Sciences Naturelles* **270**: 2308–2310.
- , J. C. MICHEL, A. G. CHABAUD, AND E. R. BRYGOO. 1972. Cycle biologique d'*Hepatozoon domerguei*; discussion sur les caracteres fondamentaux d'un cycle de coccidie. *Zeitschrift für Parasitenkunde* **38**: 250–270.
- LEVINE, N. D. 1988. The protozoan phylum Apicomplexa, Volume 1. CRC Press Inc., Boca Raton, Florida, 203 p.
- LOWICHIK, A., AND R. G. YAEGER. 1987. Ecological aspects of snake hemogregarine infections from two habitats in southeastern Louisiana. *Journal of Parasitology* **73**: 1109–1115.
- LUISELLI, L., AND F. M. ANGELICI. 1998. Sexual size dimorphism and natural history traits are correlated with intersexual dietary divergence in royal pythons (*Python regius*) from the rainforests of southeastern Nigeria. *Italian Journal of Zoology* **65**: 183–185.
- , ———, AND G. C. AKANI. 2001. Food habits of *Python sebae* in suburban and natural habitats. *African Journal of Ecology* **39**: 116–118.
- MEDLIN, L., H. J. ELWOOD, S. STICKEL, AND M. L. SOGIN. 1988. Characterization of enzymatically amplified eukaryotic 16S-like rRNA-coding regions. *Gene* **71**: 491–499.
- NADLER, S. A., AND J. H. MILLER. 1984. A redescription of *Hepatozoon mocassini* (Laveran, 1902) from *Agkistrodon piscivorus leucostoma* Troust, 1836. *Journal of Protozoology* **31**: 321–324.
- , AND ———. 1985. Fine structure of *Hepatozoon mocassini* (Apicomplexa, Eucoccidiurida) gametocytes and modifications of the infected erythrocyte plasmalemma. *Journal of Protozoology* **32**: 275–279.
- ODA, S. N., J. CHAO, AND G. H. BALL. 1971. Additional instances of transfer of reptile Hemogregarines to foreign hosts. *Journal of Parasitology* **57**: 1377–1378.
- OLEJNÍČEK, J. 1993. Plexiglas® box system for mosquito rearing. *Bulletin of the Society for Vector Ecology* **18**: 38–39.
- PAPERNA, I., T. KREMER-MECABELL, AND S. FINKELMAN. 2002. *Hepatozoon kisrae* n. sp. infecting the lizard *Agama stellio* is transmitted by the tick *Hyalomma* cf. *aegyptium*. *Parasite* **9**: 17–27.
- , AND R. LAINSON. 2003. Ultrastructural studies on the sporogony of *Hepatozoon* spp. in *Culex quinquefasciatus* Say, 1823 fed on infected *Caiman crocodilus* and *Boa constrictor* from northern Brazil. *Parasitology* **127**: 147–154.
- , AND ———. 2004. *Hepatozoon* cf. *terzii* (Sambon & Selingmann, 1907) infection in the snake *Boa constrictor constrictor* from north Brazil: Transmission to the mosquito *Culex quinquefasciatus* and the lizard *Tropidurus torquatus*. *Parasite* **11**: 175–181.
- PEIRCE, M. A. 1984. Some parasites of reptiles from Zambia and Indian Ocean islands with a description of *Haemogregarina zambiensis* sp. n. from *Dispholidus typus* (Colubridae). *Journal of Natural History* **18**: 211–217.
- PHISALIX, M. 1914. Sur une hémogregarine nouvelle, parasite de *Boodon fuliginosus* Boie, et ses formes de multiplication endogène. *Bulletin de la Société de Pathologie Exotique* **7**: 575–577.
- ROBERTSON, M. 1906. Notes on certain blood-inhabiting protozoa. *Proceedings of the Royal Physical Society of Edinburgh* **16**: 232–247.
- SAMBON, L. W., AND C. G. SELIGMANN. 1907. The haemogregarines of

- snakes. *Transactions of the Pathological Society of London* **58**: 310–370.
- SMITH, T. G. 1996. The genus *Hepatozoon* (Apicomplexa: Adeleina). *Journal of Parasitology* **82**: 565–585.
- , S. S. DESSER, AND D. S. MARTIN. 1994. The development of *Hepatozoon sipedon* sp. nov. (Apicomplexa: Adeleina: Hepatozoidae) in its natural host, the northern water snake (*Nerodia sipedon sipedon*), in the culicine vectors *Culex pipiens* and *C. territans*, and in an intermediate host, the Northern leopard frog (*Rana pipiens*). *Parasitology Research* **80**: 559–568.
- , B. KIM, AND S. S. DESSER. 1999. Phylogenetic relationships among *Hepatozoon* species from snakes, frogs and mosquitoes of Ontario, Canada, determined by ITS-1 nucleotide sequence and life-cycle, morphological and developmental characteristics. *International Journal of Parasitology* **29**: 293–304.
- , S. H. KOPKO, AND S. H. DESSER. 1996. Life cycles, morphological characteristics, and host specificity of *Hepatozoon* species infecting eastern garter snake from Ontario. *Canadian Journal of Zoology* **74**: 1850–1856.
- SPAWLS, S., K. HOWELL, R. DREWES, AND J. ASHE. 2004. A field guide to the reptiles of East Africa. A & C Black Publishers Ltd., London, U.K., p. 306–307.
- SWOFFORD, D. L. 2001. PAUP*: Phylogenetic analysis using parsimony (*and other methods), version 4. Software distributed by Sinauer Associates, Sunderland, Massachusetts.
- TELFORD, S. R. 1984. Haemoparasites of reptiles. In *Diseases of amphibians and reptiles*, G. L. Hoff, F. L. Frye, and E. R. Jacobson (eds.). Plenum Press, New York, New York, p. 385–517.
- TELFORD, JR., S. R., J. F. BUTLER, AND R. S. TELFORD. 2002. *Hepatozoon* species (Apicomplexa: Hepatozoidae) of the corn snake, *Elaphe guttata* (Serpentes: Colubridae) and the pigmy rattlesnake, *Sistrurus miliarius barbouri* (Serpentes: Viperidae) in South Florida. *Journal of Parasitology* **88**: 778–782.
- , J. A. ERNST, A. M. CLARK, AND J. F. BUTLER. 2004. *Hepatozoon sauritus*: A polytopic hemogregarine of three genera and four species of snakes in North Florida, with specific identity verified from genome analysis. *Journal of Parasitology* **90**: 352–358.
- , S. R. TELFORD III, AND J. F. BUTLER. 2002. The status of *Haemogregarina masoni* Sambon and Selingmann from *Zamensis flagelliformis* Laurenti. *Journal of Parasitology* **88**: 783–785.
- , E. J. WOZNIAC, AND J. F. BUTLER. 2001. Haemogregarine specificity in two communities of Florida snakes, with descriptions of six new species of *Hepatozoon* (Apicomplexa: Hepatozoidae) and possible species of *Haemogregarina* (Apicomplexa: Haemogregarinidae). *Journal of Parasitology* **87**: 890–905.
- THOMPSON, J. D., T. J. GIBSON, F. PLEWNIAC, F. JEANMOUGIN, AND D. G. HIGGINS. 1997. The CLUSTAL_X windows interface: Flexible strategies for multiple sequence alignment aided by quality analysis tools. *Nucleic Acids Res* **25**: 4876–4882.
- VOTÝPKA, J., M. OBORNÍK, P. VOLF, M. SVOBODOVÁ, AND J. LUKEŠ. 2002. *Trypanosoma avium* of raptors (Falconiformes): Phylogeny and identification of vectors. *Parasitology* **125**: 253–263.
- WOZNIAC, E. J., AND S. R. TELFORD. 1991. The fate of possibly two *Hepatozoon* species naturally infecting Florida black racers and watersnakes in potential mosquito and soft tick vectors: Histological evidence of pathogenicity in unnatural host species. *International Journal for Parasitology* **21**: 511–516.
- , G. L. MCLAUGHLIN, AND S. R. TELFORD, JR. 1994. Description of the vertebrate stages of a hemogregarine species naturally infecting Mojave Desert sidewinders (*Crotalus cerastes*). *Journal of Zoo and Wildlife Medicine* **25**: 103–110.
- , S. R. TELFORD, JR., D. F. DENARDO, G. L. MCLAUGHLIN, AND J. F. BUTLER. 1998. Granulomatous hepatitis associated with *Hepatozoon* sp. meronts in a southern water snake (*Nerodia fasciata pictiventris*). *Journal of Zoo and Wildlife Medicine* **29**: 68–71.